

# Browpexy Through the Upper Lid (BUL): A New Technique of Lifting the Brow With a Standard Blepharoplasty Incision

Aesthetic Surgery Journal  
31(2) 163–169  
© 2011 The American Society for  
Aesthetic Plastic Surgery, Inc.  
Reprints and permission:  
[http://www.sagepub.com/  
journalsPermissions.nav](http://www.sagepub.com/journalsPermissions.nav)  
DOI: 10.1177/1090820X10395009  
[www.aestheticsurgeryjournal.com](http://www.aestheticsurgeryjournal.com)  


Brian D. Cohen, MD; Alyssa J. Reiffel, MD; and Henry M. Spinelli, MD

## Abstract

**Background:** Browpexy returns the brow to an anatomical, aesthetically-appealing location on the upper face. Recently, browlifting techniques have evolved from aggressive, open approaches toward less invasive, limited-incision techniques. Browpexy through the upper lid (BUL), an innovative technique based on earlier practices, anchors the underlying brow soft tissue to the bone, allowing for stabilization. Furthermore, this procedure can be performed concomitantly with an upper eyelid blepharoplasty through the same access incision.

**Objective:** The authors evaluate the efficacy of BUL in patients with ptotic eyebrows requiring stabilization and/or elevation and in patients with prominent brow fat pads.

**Methods:** The charts of 21 patients who were treated with BUL by the senior author (HMS) between February 2007 and October 2008 were retrospectively reviewed.

**Results:** The age range of the 21 patients in this study was 54 to 70 years. Twelve patients were men; nine were women. Each patient presented with complaints of tired-appearing or “weighed-down” upper eyelids. All patients were uniformly happy with their postoperative aesthetic results. There were no major immediate or long-term complications (including, but not limited to, uneven postoperative brow position, loss of suspension, frontal nerve injury, hematoma, infection, or wound dehiscence). No patients required reoperation for recurrent brow ptosis or upper lid deformity.

**Conclusions:** BUL is ideal for patients with ptotic eyebrows who need brow stabilization and/or elevation, as well as for patients with prominent brow fat pads who require stabilization. BUL achieves excellent results through a standard upper eyelid blepharoplasty incision, and allows the surgeon to perform a concomitant upper eyelid blepharoplasty and browpexy without a traditional coronal, scalp, or forehead incision.

## Keywords

blepharoplasty, browpexy, ptosis, oculoplastics, minimally-invasive surgery

Accepted for publication May 11, 2010.

Browlifting can be accomplished through a variety of techniques, some of which remain under debate.<sup>1-3</sup> All of these methods have been well documented and can achieve aesthetically pleasing results. Historically, the procedure dates back to 1919, when Passot<sup>4</sup> described elliptical excisions to elevate the brows and diminish crow’s feet. In the 1930s, Lexer<sup>5</sup> and Claoue<sup>6</sup> described combination procedures in which browlifting could be accomplished with standard rhytidectomy incisions. By the late 20th century, browlifting techniques began to evolve away from more aggressive, open approaches (such as those performed through a coronal or anterior hairline incision) toward less invasive limited-incision techniques (with or without an endoscope).<sup>7-12</sup> There has also been a rise in the popularity of browlifting performed through alternate approaches, such as through an upper blepharoplasty incision. Such procedures are

effective in both men and women for aesthetic improvement of the eyelid and eyebrow, but can be especially useful in men who require more conservative periorcular surgery or

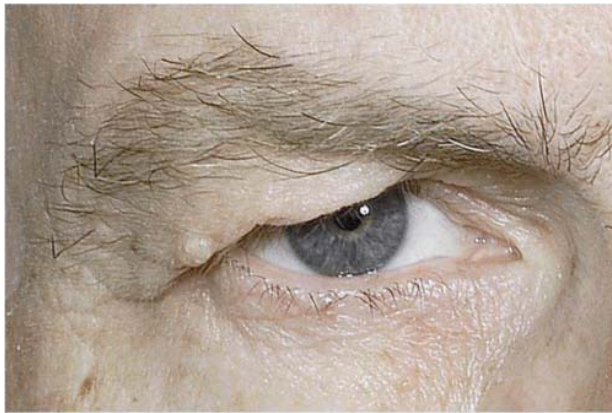---

From the Division of Plastic and Reconstructive Surgery at New York Presbyterian Hospital, Weill Cornell Medical Center, New York, NY. The content of this paper was presented in part at the annual meeting of the American Society of Plastic Surgeons (ASPS) in Baltimore, Maryland, October 2007.

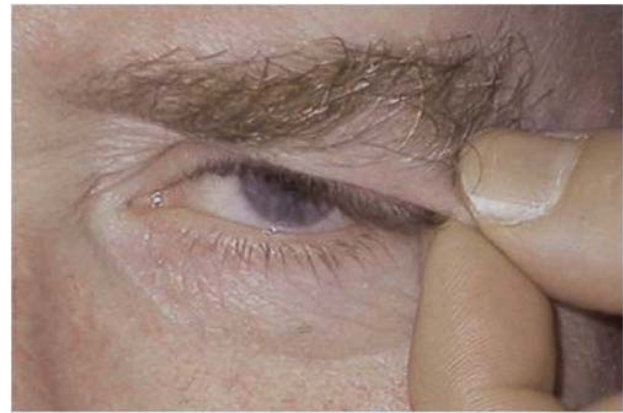## Corresponding Author:

Dr. Henry M. Spinelli, Division of Plastic and Reconstructive Surgery, Weill Cornell Medical Center, 875 Fifth Avenue, New York, NY 10021, USA.

E-mail: [hmspinelli@aol.com](mailto:hmspinelli@aol.com)



**Figure 1.** This 61-year-old man presented to the senior author (HMS) for blepharoplasty. This is a good example of a patient with mobile, ptotic brows.



**Figure 2.** A preoperative pinch test is performed to determine the mobility and extent of upper eyelid skin excision on the patient shown in Figure 1. Excision of this seemingly redundant skin and subcutaneous tissue would create an unnatural and nonanatomic convergence of the thick brow fat pad with the thin upper eyelid.

who cannot camouflage the more traditional incisions due to hair loss.

In 1982, Sokol and Sokol<sup>13</sup> published their version of a transblepharoplasty brow suspension. The evolution of such procedures continued into the 1990s, when Paul<sup>14</sup> published descriptions of a periorbital, transblepharoplasty browlift with suture anchoring of the soft tissues above the orbital rim. Ramirez's work, published in 1996 and similar to Paul's, expands on the transpalpebral approach with the addition of an endoscope to aid in dissection. He also describes suture-anchoring the retroorbicularis oculi fat to the periosteum of the orbital rim.<sup>15</sup> Zarem et al<sup>16</sup> reported performing browpexy at the time of upper lid blepharoplasty through fixation of the lateral orbicularis muscle to the arcus marginalis. More recently, Pascali et al<sup>17</sup> described a browpexy technique that utilizes the Endotine device (Coapt Systems, Inc., Palo Alto, California) to secure the superficial temporal fascia to the deep temporal fascia in a more anatomic location. Although all of these previously published reports are pioneering and have theoretical merit, the practical considerations of ease of implementation by the average surgeon and long-term predictable stability of soft-tissue-to-soft-tissue fixation without direct bony anchoring have drawbacks.

For patients with mobile, ptotic eyebrows (Figure 1), selection of the best technique to achieve stabilization (and even lifting) should be guided by the patient's facial profile and general appearance. In patients with high foreheads or those not needing a full, formal browlift (and especially in men with thinning hair or baldness), our technique of browpexy through the upper lid (BUL) is ideal, as it allows for brow stabilization with or without a lateral lift by direct bony fixation. BUL can be performed with a concomitant upper eyelid blepharoplasty through the same access incision. BUL also allows for brow stabilization alone in those patients (male and female) in whom lateral hooding is attributable to brow ptosis and/or instability; it will not cause blending of the thin upper eyelid skin with that of the thicker brow pad.

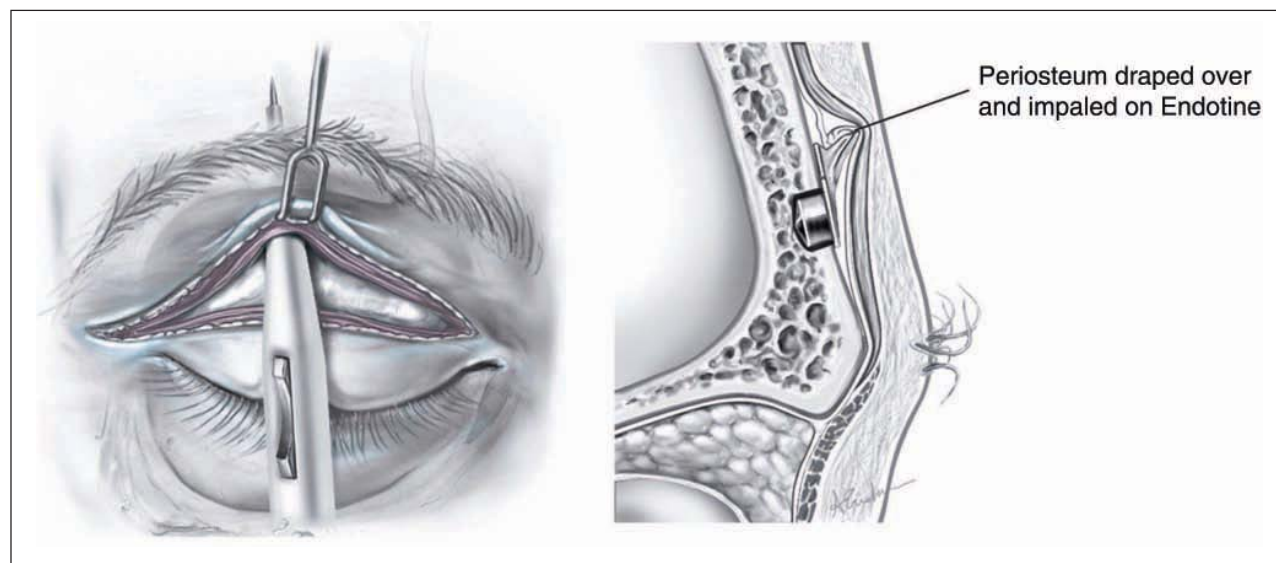
Our technique accomplishes the aforementioned goals while reducing the risk of potential complications, adding very little operative time to a standard upper eyelid blepharoplasty and requiring no additional incisions. Although others have described suture fixation of the lateral brow via a transblepharoplasty approach, BUL is an innovative technique that anchors the underlying soft tissue of the brow to bone to ensure adequate fixation and excellent long-term aesthetic results.

## METHODS

Between February 2007 and October 2008, 21 patients (12 men and nine women) were treated with the BUL technique by the senior author (HMS), and their charts were retrospectively reviewed. Each of the patients presented for upper blepharoplasty, initially complaining of tired-appearing upper eyelids and/or the feeling of "weighed-down" upper eyelids. After extensive consultation with the senior author, each patient understood that his or her cosmetic deformity was not only attributable to excess skin of the upper lid but to a ptotic brow as well.

During preoperative assessment, a pinch test was performed to determine the extent of upper eyelid skin excision (Figure 2). In patients with excessive lateral brow ptosis, excision of too much upper eyelid skin and the ensuing dog-ear deformity would exacerbate their cosmetic problem and possibly lead to functional deficits. These patients were determined to be ideal candidates for BUL, as the procedure allows fixation of the brow to the superior orbital rim to provide stabilization while also lifting the brow.

Prior to entering the operating suite, patients were marked in the upright position. The brow was suspended digitally prior to any markings. The inferior aspect of the



**Figure 3.** A cephalic dissection is performed with a transeyelid approach to orbital rim and frontal bone (*left*). The Endotine fixation device is shown from a parasagittal view (*right*).

eyebrow hairline acted as a landmark with reference to the superior orbital rim. The distance the brow hairline would be raised was measured. If an upper eyelid blepharoplasty was also planned, appropriate markings were made only after the browpey markings were completed.

A standard upper eyelid blepharoplasty incision was utilized in all cases. When a concomitant blepharoplasty was performed, skin was resected as appropriate, taking into account the new brow position after elevation and/or stabilization. The skin and orbicularis muscle were raised together from lateral to medial with an instrument to pull the skin muscle flap superonasally while applying digital traction laterally. Fat was resected from the preaponeurotic space when appropriate. Then, a cephalic dissection was performed in the submuscular plane without incising the periosteum (Figure 3). At the level of the orbital rim, the periosteum was scored with electrocautery and elevated 1.5 to 2 cm above the superior and lateral orbital rim. If necessary, the brow fat pad was debulked with electrocautery; however, we preferred not to resect this fat pad in men and most women in order to maintain the normal anatomic fullness in this area.

The Endotine (Coapt Systems, Inc., Palo Alto, CA; \$310 per device, \$620 per patient) device was placed for brow fixation.<sup>18,19</sup> In the majority of cases, the device was seated centrally over the brow, as this provided for the most aesthetically pleasing results. The device can be positioned more laterally, however, to allow for greater convexity of the eyebrow, especially in female patients. Once the ideal location was selected, a hole was drilled into the supraorbital rim at the appropriate level with a mechanical handheld drill. The device was then seated into the hole until it was flush with the frontal bone. The superior cut edge of the periosteum and the attached overlying eyebrow were then elevated up and over the tines. A 4-0 absorbable monofilament suture was placed to secure the elevated periosteum to the device

(Figure 4). Digital pressure was applied to engage the overlying soft tissue to the device. The blepharoplasty incisions were then closed and a sterile dressing was applied.

## RESULTS

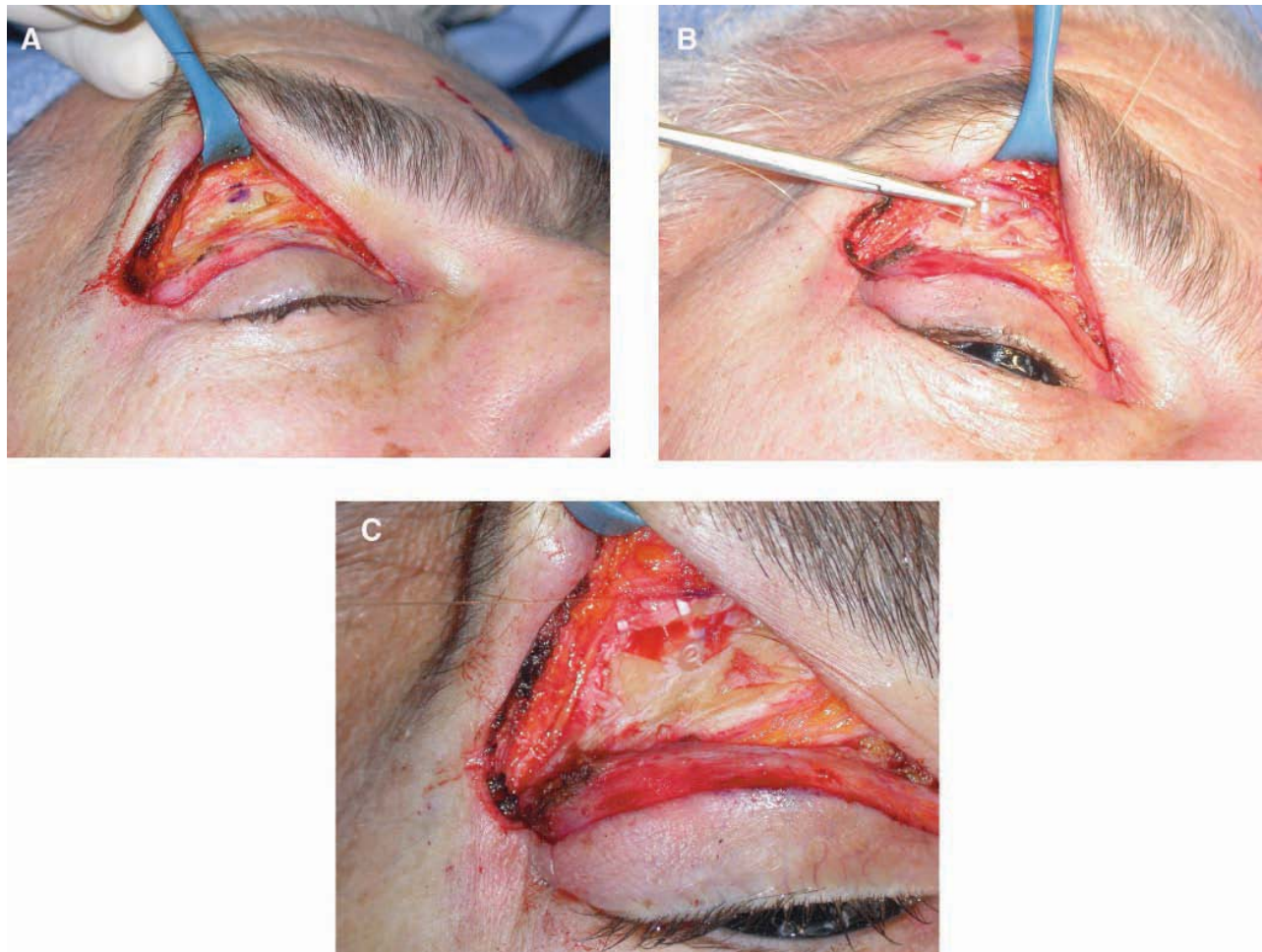
The age range of the patients in this series was 54 to 70 years. During the follow-up period (which averaged 1.6 years; range, one to two years), no patients required reoperation for recurrent brow ptosis or upper lid deformity. Of the 21 patients, all were uniformly pleased with their aesthetic results. There were no major immediate or long-term complications (including, but not limited to, uneven postoperative brow position, loss of suspension, or frontal nerve injury). There were no instances of hematoma, infection, or wound dehiscence.

## DISCUSSION

Eyebrows occupy a prominent and expressive position in the upper third of the face. As a result of this conspicuous location, age-related changes such as wrinkling and ptosis are a leading complaint of patients seeking cosmetic surgery. Therefore, brow rejuvenation (or restoration to a more youthful location) has been a goal of plastic surgeons for the past century.

The complex anatomy of the eyebrow region includes components from the nearby eyelid, as well as from the eyebrow itself. The relatively thin eyelids can be viewed as trilamellae "squeegee-like" structures supported across the orbital rim by the medial and lateral canthal tendons. The three lamellae include an outer covering of thin skin overlying the tarsus and preseptal areas, with minimal subcutaneous tissue. The inner, posterior lamella consists of the





**Figure 4.** (A) After the periosteum is elevated to a level above the superior and lateral orbital rim, the appropriate position for the brow fixation device is marked. (B, C) A monofilament suture is placed to secure the periosteum to the device.

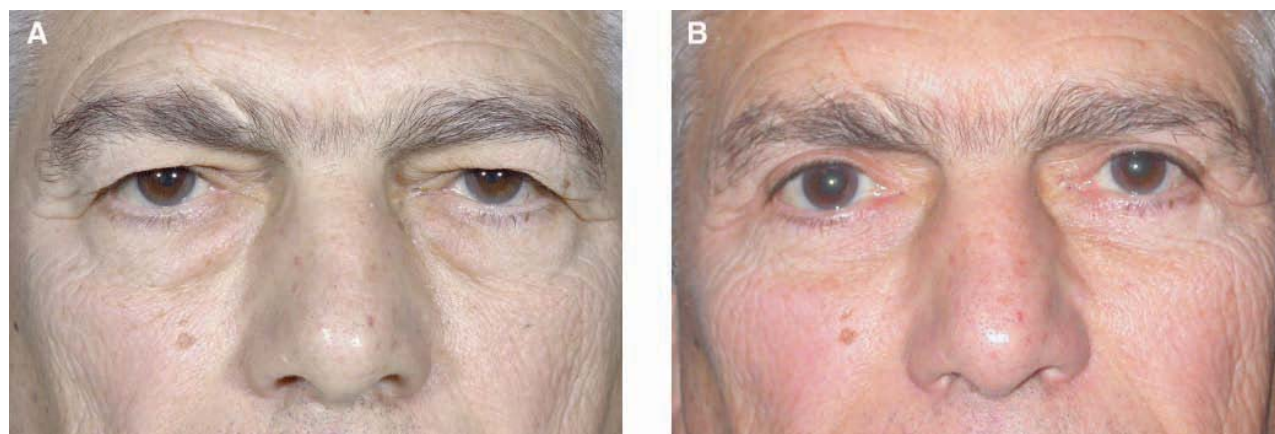
tarsal plate and a mucosal lining, or conjunctiva, which provides a near-frictionless surface for the globe and eyelid to glide across one another. The supportive middle layer includes the orbicularis oculi muscles, with preorbital and preseptal portions lying anterior to the tarsal plate and orbital septum, respectively. The orbicularis muscles are contiguous with the superficial musculoaponeurotic system (SMAS), platysma, and frontalis muscles. The frontalis and orbicularis oculi muscles converge at the level of the relatively thick eyebrow. Fixation occurs deep to this plane during transblepharoplasty browlifting procedures.

The eyebrow region owes its expressiveness to the movable SMAS plane, which glides over a rigidly fixed bone and periosteal plane. The brow fat pad is a distinct entity and, through its dense attachments, serves to secure the brow to the supraorbital ridge and thereby enhance movement of the eyebrow. The fat pad is more prominent laterally than medially and commonly extends inferiorly into the preorbital septal plane. It is distinct from the preaponeurotic, postseptal fat encountered during blepharoplasty

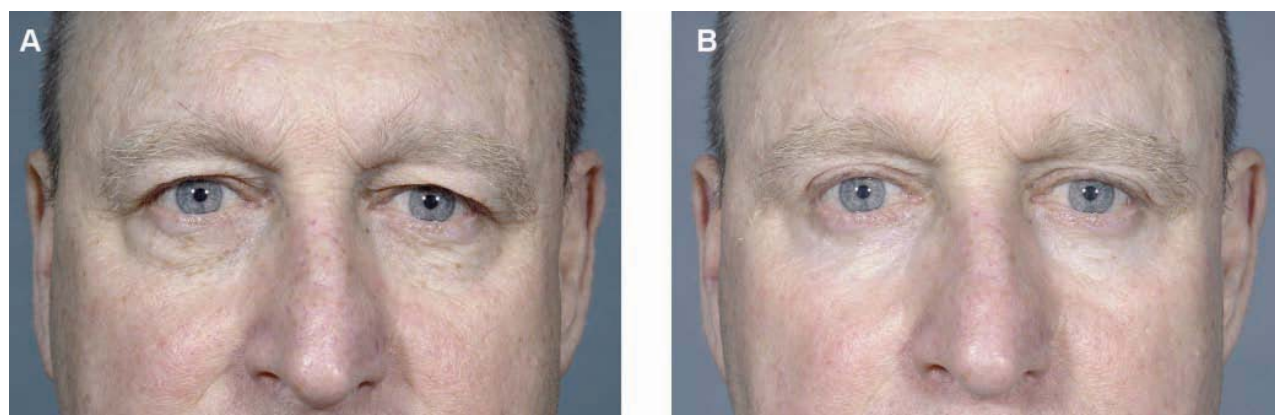
and may need to be addressed separately during a lateral browlift.

Traditional superior or more anterior scalp incisions and their required dissections can be prominent and aesthetically unappealing, as well as lead to alopecia and other sequelae. Furthermore, in a select population, they may be unnecessary and undesirable. This challenge, in part, led to the development of more limited incision techniques to lift the eyebrows. A thorough understanding of facial anatomy has taught us that complete upper face rejuvenation can be performed through upper lid blepharoplasty incisions.

Through cadaveric studies, Knize<sup>20</sup> showed that the senescent changes of the brow are more severe and occur earlier in the lateral versus medial brow. In a review article, Freund and Nolan<sup>21</sup> surveyed plastic surgeons and cosmetologists on the ideal brow position. The consensus was that the medial brow should be located at or below the supraorbital rim and that, in women, the shape should have an “apex lateral slant.” BUL restores the brow to this more aesthetic location and is ideal for correction of lateral



**Figure 5.** (A) This 69-year-old man presented with ptotic brows and significant hooding of brow tissue. (B) Eleven months after the browpexy through the upper lid procedure, the brow has been stabilized in a more anatomic position.



**Figure 6.** (A) This 58-year-old man presented with ptotic brows, a high forehead, and male-pattern baldness. (B) Eight months after brow stabilization and upper eyelid blepharoplasty.

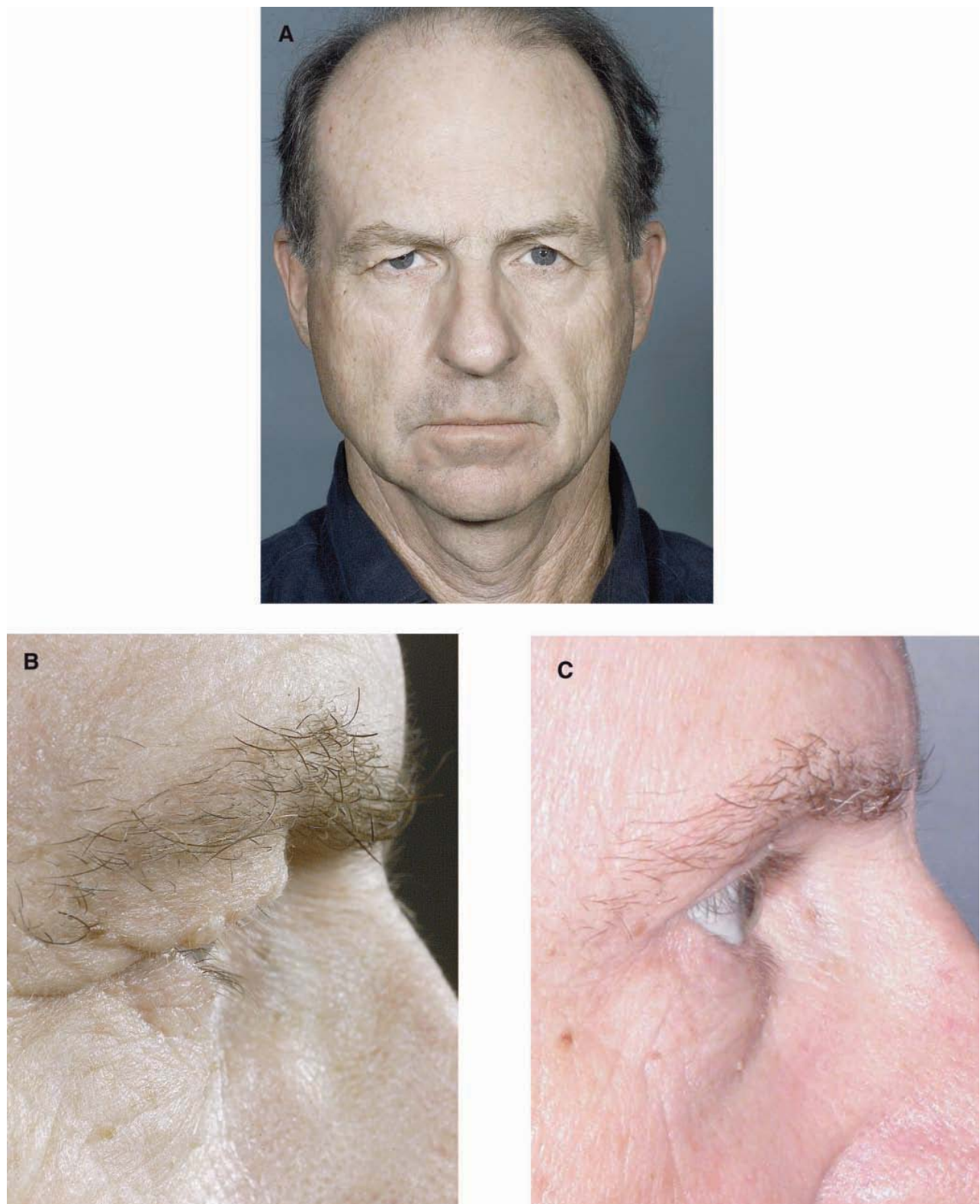
brow ptosis<sup>22</sup> in patients with male-pattern baldness, high foreheads,<sup>15,23</sup> and those who do not want a traditional browlift (Figures 5-7).

BUL achieves particularly excellent results for patients with mobile, ptotic brows who may also desire upper eyelid blepharoplasty. These patients may require a lift (or simply stabilization) of the lateral one-third to one-half of their brow not only to enhance the cosmetic effect of the blepharoplasty but also to prevent overresection of pseudoexcess skin. Direct excision of this apparently redundant skin and subcutaneous tissues of the upper eyelids draws the brow even more inferiorly and results in an unnatural and nonanatomic convergence of the thick brow fat pad and the thin upper eyelid. Furthermore, excision of excess tissue and the resultant lateral dog-ear can further accentuate ptosis in an already mobile brow. Thus, patients with a mobile brow, both male and female, need brow stabilization as opposed to tissue resection at the eyelid level to prevent accentuation of eyebrow ptosis and blending of the thick brow fat pad with the thin upper eyelid skin. If a browlift and stabilization are not performed concomitantly, the lateral eyebrow will be drawn downward

over the orbit, producing a "severe, stern appearance."<sup>7</sup> In addition, the patient may be left with corneal exposure due to excessive skin excision.

There is no gold-standard technique for browlifting. There continues to be an evolution of approaches as well as methods for fixation of the brow. Transblepharoplasty brow suspension can be accomplished with a variety of suture techniques. However, there is a significant risk of "cheese-wiring," as seen in patients undergoing SMAS plication during rhytidectomy.<sup>24</sup> Although the senior author has previously written about brow fixation with a suture between the soft tissue of the brow and the periosteum, recent experience has shown that reliable fixation is best accomplished with a device such as the Endotine.<sup>25</sup> This (or a similar) system is inexpensive, easy to place, and provides direct brow fixation to the bone. As the device is seated in the subperiosteal plane, there is no dimpling of the skin, excessive pull of the overlying soft tissues, or "cheese-wiring." Furthermore, the procedure is safe, quick, and easy to learn, and it provides excellent long-term fixation and reproducibility. Alternative bony fixation techniques, even as simple as placing a suture,





**Figure 7.** (A, B) This 61-year-old man presented with ptotic brows, male-pattern baldness, and hooding of the brow over the eyelid. (C) Six months after browpexy through the upper lid and concomitant upper eyelid blepharoplasty, the patient's ptotic brow has been restored to a position at the supraorbital rim and the appropriate amount of excess skin has been removed.

would require partial-thickness drill holes into the anterior table of the skull. This would be more time-consuming; require more equipment, skills, and experience; and generally be less applicable to the average surgeon.

## CONCLUSIONS

Although techniques to lift the brow have evolved over the past century, the ultimate goal of this type of procedure is to return the brow to an anatomical and aesthetically appealing location on the upper face. In patients with excessively mobile and/or ptotic brows, an optimal upper eyelid blepharoplasty requires the brow to be addressed. Therefore, BUL is ideal for patients with ptotic eyebrows who need brow stabilization and/or elevation, in whom the primary objective is to achieve the best possible upper eyelid blepharoplasty result. BUL achieves excellent results through a standard upper eyelid blepharoplasty incision and allows the surgeon to concomitantly perform a browpexy and an upper eyelid blepharoplasty without requiring incisions or dissections outside the primary zone of intended efficacy—namely, the upper eyelids and eyebrow. It is relatively simple, does not have a steep learning curve to be mastered, and is universally applicable in the blepharoplasty population. Its straightforward technology and minimal time consumption make it applicable in any outpatient venue.

## Disclosures

The authors declared no conflicts of interest with respect to the authorship and publication of this article.

## Funding

The authors received no financial support for the research and authorship of this article.

## REFERENCES

- Matarasso A, Hutchinson O. Evaluating rejuvenation of the forehead and brow: an algorithm for selecting the appropriate technique. *Plast Reconstr Surg* 2000;106:687-696.
- Elkwood A, Matarasso A, Rankin M, Elkwitz M, Godek C. National plastic surgery survey: brow lifting techniques and complications. *Plast Reconstr Surg* 2001;108:2143-2150.
- Chiu ES, Baker DC. Endoscopic brow lift. *Plast Reconstr Surg* 2003;112:628-663.
- Passot R. La chirurgie esthétique des rides du visage. *Presse Med* 1919;27:258-260.
- Lexer E. *Die Gesamte Wiederherstellungs-Chirurgie*. Vols 1-2. Leipzig, Germany: Jahann Ambrosius Barth; 1931.
- Claoue C. La ridectomie cervico-faciale par accrochage parieto-temporo-occipital et resection cutanee. *Bull Acad Med (Paris)* 1933;109:257-265.
- Knize DM. Limited-incision forehead lift for eyebrow elevation to enhance upper blepharoplasty. *Plast Reconstr Surg* 1996;97:1334-1342.
- McKinney P, Mossie RD, Zukowski ML. Criteria for forehead lift. *Aesthetic Plast Surg* 1991;15:141-147.
- Vasconez LO. The use of the endoscope in brow lifting. Annual meeting of the American Society of Plastic and Reconstructive Surgeons. Washington, D.C.; 1992.
- Paul MD. The evolution of the brow lift in aesthetic plastic surgery. *Plast Reconstr Surg* 2001;108:1409-1424.
- Tabatabai N, Spinelli HM. Limited incision nonendoscopic brow lift. *Plast Reconstr Surg* 2007;119:1563-1570.
- Langsdon PR, Metzinger SE, Glickstein JS, et al. Transblepharoplasty brow suspension: an expanded role. *Ann Plast Surg* 2008;60:2-5.
- Sokol AB, Sokol TP. Transblepharoplasty brow suspension. *Plast Reconstr Surg* 1982;69:940-944.
- Paul MD. Subperiosteal transblepharoplasty forehead lift. *Aesthetic Plast Surg* 1996;20:129-13415.
- Ramirez OM. Transblepharoplasty forehead lift and upper face rejuvenation. *Ann Plast Surg* 1996;37:577-584.
- Zarem HA, Resnick JI, Carr RM, et al. Browpexy: lateral orbicularis muscle fixation as an adjunct to upper blepharoplasty. *Plast Reconstr Surg* 1997;100:1258-1261.
- Pascali M, Gualdi A, Bottini DJ, et al. An original application of the Endotine Ribbon device for brow lift. *Plast Reconstr Surg* 2009;124:1652-1661.
- Evans GR, Kelishadi SS, Ho KU. "Heads up" on brow lift with Coapt Systems' Endotine forehead technology. *Plast Reconstr Surg* 2004;113:1504-1505.
- Coapt Systems. Available at: <http://www.coaptsystems.com/products/TransBleph.html>. Accessed January 13, 2011.
- Knize DM. An anatomically based study of the mechanism of eyebrow ptosis. *Plast Reconstr Surg* 1996;97:1321-1333.
- Freund RM, Nolan WB, 3rd. Correlation between brow lift outcomes and aesthetic ideals for eyebrow height and shape in females. *Plast Reconstr Surg* 1996;97:1343-1348.
- McCord CD, Doxanas MT. Browplasty and browpexy: an adjunct to blepharoplasty. *Plast Reconstr Surg* 1990;86:248-254.
- Knize DM. Limited incision forehead lift for eyebrow elevation to enhance upper blepharoplasty. *Plast Reconstr Surg* 2001;108:564-567.
- Stuzin JM, Baker TJ, Baker TM. Refinements in face lifting: enhanced facial contour using Vicryl mesh incorporated into SMAS fixation. *Plast Reconstr Surg* 2000;105:290-301.
- Spinelli HM, Elahi E, Lewis AB. *Atlas of Aesthetic Eyelid and Periocular Surgery*. Philadelphia: Saunders; 2003.